

# Transcutaneous laser-induced interstitial thermotherapy of nodular goiter

Valery A. Privalov <sup>\*a,b</sup>, Oleg V. Seliverstov <sup>b</sup>, Jean A. Revel-Muroz <sup>a</sup>, Alexander V. Lappa <sup>\*\*a,c</sup>,  
Ravil U. Giniatullin <sup>a</sup>

<sup>a</sup>Chelyabinsk State Institute of Laser Surgery, pr. Pobedy 287, Chelyabinsk, 454021, Russia

<sup>b</sup>Chelyabinsk State Medical Academy, Vorovskogo 64, 454080, Russia

<sup>c</sup>Chelyabinsk State University, Br. Kashirinykh 129, Chelyabinsk, 454021, Russia

## ABSTRACT

In the experiment on 41 dogs the possibilities of Nd:YAG (1064nm) and diode lasers (805nm) usage for thermotherapy of thyroid gland was grounded. We founded the regimes of laser irradiation causing local destruction of thyroid glands without damage of surrounding organs and tissues. An intratissue dynamic thermometry control in the thyroid and surrounding tissues and their histological analysis were used for determination of the operating mode. The thermometry was performed with the help of an original setup, specimens for the analysis were taken in the period from 1-3 to 130 days after the laser irradiation. The results of the experiments gave occasion to the use of intrathyroid local laser hyperthermia in the treatment of 15 patients with recurrent nodal and multinodal euthyroid goiter and 2 patients with inoperable (incurable) medullary thyroid cancer. The laser thermotherapy was fulfilled transcutaneously with ultrasonic control. No complications were registered during the irradiation and the nearest postoperative period. The dynamic ultrasonic examination of the patients carried out for 3-18 months showed a positive effect in all cases.

**Keywords:** Laser, thyroid gland, goiter, surgery.

## 1. INTRODUCTION

According to World Health Organization data (1994) about 300 million patients with goiter and hypothyroidism are diagnosed all over the world. Increase of thyroid disease rate occurs substantially due to nodular forms of goiter and thyroid cancer<sup>1</sup>.

Conservative treatment of goiter does not always have an adequate positive effect. At the same time methods used in surgical correction of thyroid disease are traumatic, quite often lead to complications and do not prevent recurrence of disease<sup>20,22</sup>. Frequency of postoperative recurrences of various goiter forms runs up to 39%<sup>18,6</sup>. Repeated thyroid operations are characterized by technical difficulties resulting in increase of surgical intervention risk and hazard of postoperative complications<sup>4,7</sup>. That is why development of new methods of thyroid disease treatment and their introduction to surgical practice become an actual problem. This particularly concerns the methods which decrease the complications and recurrences risks, shorten the hospitalization period, and reduce the treatment expenses<sup>11</sup>.

During the last 20-30 years researchers have taken interest in possibility to effect on cells of tissues and organs including tumors by high temperature to kill them. Thermal therapy of tumors, local hyperthermia with electrocoagulation or RF and microwave hyperthermia have not become widespread due to considerable injury of adjacent tissues. The attempts to use lasers for interstitial destruction of tumors of different locations are being undertaken during last years<sup>3,17</sup>. However Nd:YAG and diode lasers have never been applied in the local interstitial destruction of thyroid gland.

The aim of this work was to ground the possibility of application of Nd:YAG and diode lasers radiation for focal destruction of thyroid gland on the basis of experimental study of reparative and adaptive processes, and to develop the new low-invasive method for treatment of thyroid nodular growths.

---

\* Correspondence: Email: [privalov@cgilh.chel.su](mailto:privalov@cgilh.chel.su)

\*\* Correspondence: Email: [lappa@cgilh.chel.su](mailto:lappa@cgilh.chel.su) or [lappa@cgu.chel.su](mailto:lappa@cgu.chel.su), Telephone: 7 3512 189235; Fax: 7 3512 420925

## 2. MATERIALS AND METHODS

To determine parameters and optimal regimes for local interstitial laser destruction and to study dynamics of inflammatory and reparative processes in thyroid and adjacent organs and tissues the experiment in 41 mature mongrel dogs weighting 10 to 20 kg was carried out.

All animals were divided into three groups. The first group included 5 control animals to study anatomical, histological, morphometric characteristics of thyroid structure and topography of cervical organs.

In the second basic group including 31 animals the experiment was carried out to study effect of local Nd:YAG laser irradiation of thyroid tissue with subsequent histological examination after 1-3 days, 5-6 days, 10-12 days, 20 days, 30-36 days, 95-130 days.

The third group included 5 animals in which thermometry in thyroid and surrounding tissues during diode laser (805 nm) irradiation was performed to select optimal operating mode for focal destruction.

The puncture method for laser energy delivery through monofiber optical fiber to thyroid tissue was modeled in the experiment. The animals were anesthetized with an intravenous injection of calipsol and then intubated with room air. The thyroid lobes were surgically denuded; the fiber was introduced through a needle to the depth of 5-7 mm; and the needle was extracted by the fiber. After that one lobe, then the other one were exposed to laser radiation (see Fig. 1).

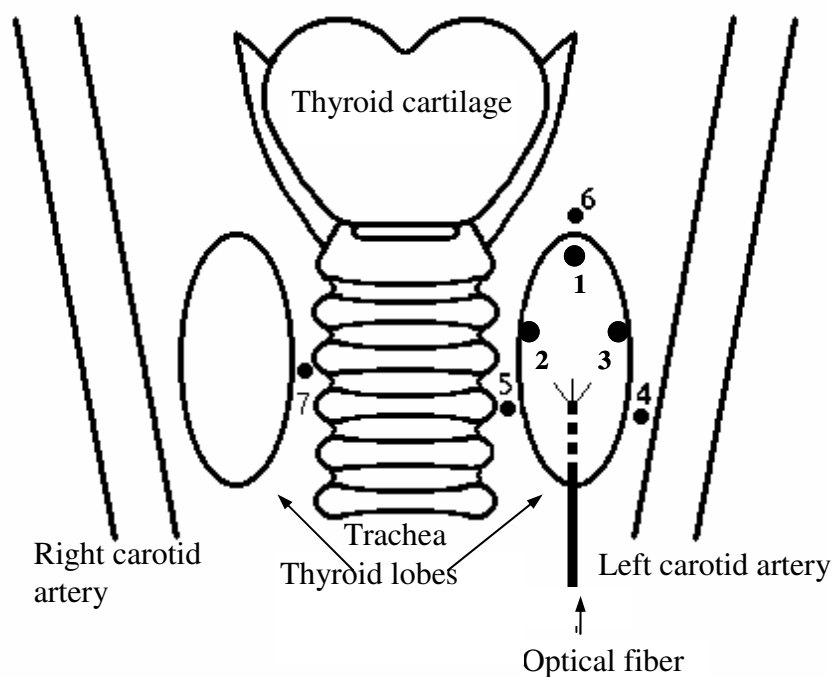


Fig. 1. Optical fiber and temperature detectors location in experiment.

The following temperature detectors and their location in tissues are numerated: 1 - under capsule of lobe in front of the fiber tip; 2 - under capsule of lobe on internal surface; 3 - under capsule of lobe on external surface; 4 - between lobe and neurovascular bundle; 5 - between lobe and trachea; 6 - in soft tissues at upper pole; 7 - between trachea and opposite thyroid lobe.

Postoperative wound was layerwise sutured tightly. After surgery general state of the dogs, behavioral reactions, mastication function, deglutition function, vocal function, and wound healing were evaluated. Sutures were removed after 6-7 days. The animals were cared and feed in ordinary way.

Nd:YAG laser (wavelength 1064 nm, continuous mode) and diode laser (wavelength 805 nm, pulse mode) were used as a source of laser radiation. The energy was delivered to a target with quartz monofiber diameter of 0.4 mm in polymer covering with total optical fiber diameter of 1 mm. Output power of Nd:YAG laser beam at the fiber end ranged from 2 to 7 W, exposure time was from 30 s to 4 min. (see Table 1).

Table 1 – Regimes of Nd:YAG Laser irradiation of Thyroid

Power, W	Time, min.					Total number of experiments
	0.5	1	2	3	4	
	Number of experiments					
2			1	2	1	4
3	1	1	23	24	2	51
5		2	1		1	4
7			1			1
Total						60

During diode laser irradiation, operation regimes were tested with average power of 3 W remained invariable but the pulse and pause duration as well as the total time of irradiation changed. Time of pulses and pauses amounted to 2-4 ms, 3-6 ms, 4-8 ms, 10-16 ms, 25-50 ms. Total time of exposure ranged from 1 to 4 minutes (see Table 2).

Table 2 –Diode laser operation modes and temperature changes in points of measurement.

Power	Duration		Temperature in the points of measurement			Total number of tests
	Pulse, ms	Pause, ms	1	2	3	
3 W	2	4	45	41	41	3
	3	6	42	41	41	1
	4	8	42	41	41	2
	10	16	62	45	50	3
	25	25	78	53	62	1

The animals were withdrew from the experiment using intravenous injection of 10 ml of 7.5% potassium chloride solution. Histopathological examination was carried out. For microscopic examination thyroid, trachea, neurovascular bundle, esophagus, and muscle samples were taken. These specimens were fixed in 10% neutral formalin solution.

During the laser thyroid destruction dynamic monitoring of temperature in tissues was performed using original setup for tissue thermometry in strong laser radiation fields<sup>12</sup>. It includes a set of miniature semiconductor detectors, amplifier, multichannel analog-digital converter and computer with software for recording, recalculation, and graphical result presentation. The setup allows to measure interstitial temperature in 7 points with time resolution of 1 ms. The size of thermometers is approximately 1 mm (see Fig.2).

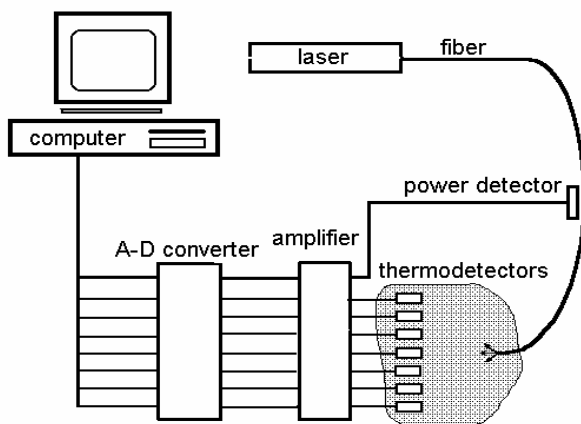


Fig.2. The setup for measurement of temperature in biological tissues.

The detectors were installed and fixed in thyroid tissue and surrounding tissues of cervix by sewing with noose sutures in the chosen points (see Fig.1). The distance between the fiber tip and detectors was 0.8-3 cm.

Analysis of hormonal status before and after Nd:YAG laser irradiation was fulfilled by method of solid-phase immunoenzymometric assay using BIOMERICA reagents to study levels of thyroxine (T4), triiodothyroxine (T3), and thyroid stimulating hormone (TSH).

After experimental development and validation of the new method for focal laser thyroid destruction (without lesions of surrounding tissues and organs) the clinical approbation of thyroid nodule destruction in 15 patients diagnosed with recurrent nodular/multinodular euthyroid goiter and in 2 patients with inoperable (incurable) medullary thyroid cancer was carried out. Nodule destruction was performed transcutaneously by puncture method under ultrasonic control (ultrasonic scanner ALOKA SSD 650, 7,5MHz probe). All patients had been operated earlier and diagnoses were verified by histological examination of tissue samples from surgery as well as by trepanobiopsy of nodules directly before laser destruction.

### 3. RESULTS AND DISCUSSION

To select the optimal Nd:YAG laser operating mode for the focal destruction of thyroid tissue, the power from 2 to 7 W and irradiation time from 30s to 4 min were tried. As a result of experiment and histological examination of thyroid samples from dogs it was ascertained that 5 W power causes the coagulation necrosis in parenchyma irrespective of exposure time. During the further reparation the necrosis was replaced with coarse-fibered connective tissue scar. Intact glandular tissue was represented by single small foci with severe dystrophic and necrobiotic changes in them. (Fig 3.)

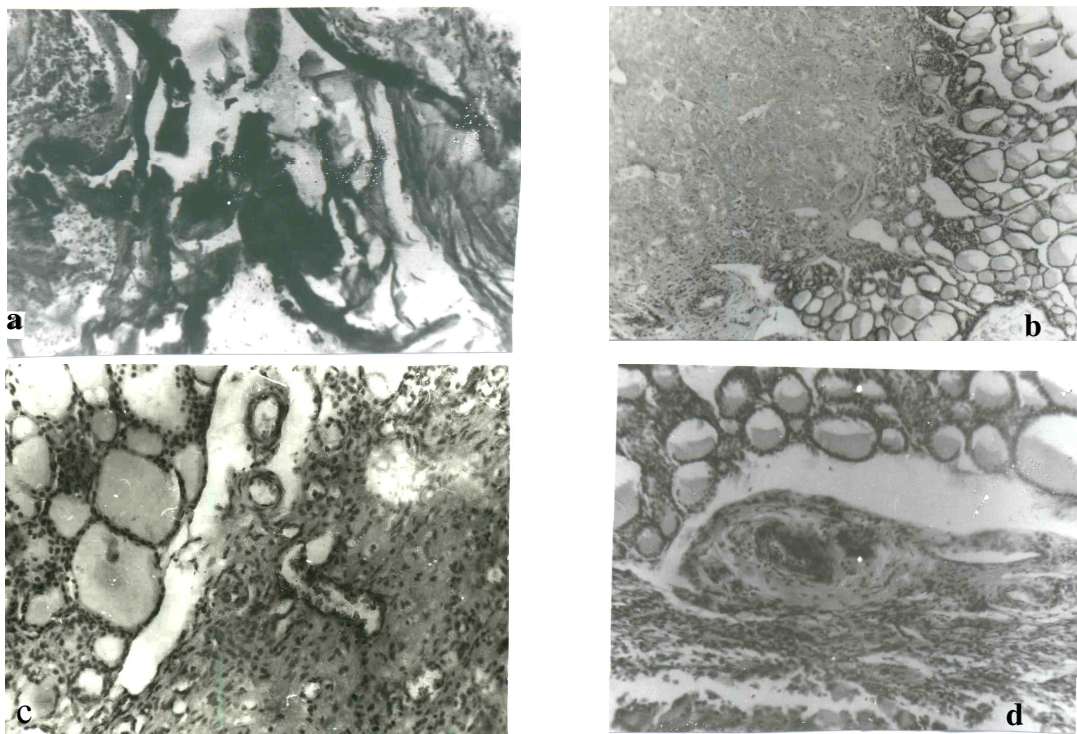


Fig.3 Histological changes in thyroid gland after Nd:YAG irradiation. Hematoxylin and eosin staining.

a – burn eschar along the destruction focus border, fibrin and admixture of hemolysed erythrocytes in the laser focus lumen. x 300; b – coagulation necrosis focus clearly bordered from the intact tissue of the gland. x 150; c – granulation tissue formation in the necrosis focus. x 150; d – mature vascularized connective tissue.

In these cases the evident changes in adjacent tissues- in neurovascular bundles, trachea, muscles- with necrosis of large and small nerve trunks and arterial walls of various sizes, inflammatory infiltration of trachea and adjacent cellular tissue appeared. (In one case the defect of tracheal wall developed).

2 W power with exposure time from 2 to 4 min did not induce full destruction at the site of laser exposure that was indicated by intact parenchyma of thyroid.

At 3 W power with irradiation time of 2 min destruction focus was 1.0x0.3x0.3 cm in size and for irradiation time of 3 min it was 1.0x 0.5x0.5 cm that suited our requirements better.

During the first 3 days after Nd:YAG laser irradiation in continuous operating mode, power of 3 W and time of 180 s the local destruction of all tissue structures of thyroid as coagulation necrosis of mean volume of 90-100 mm<sup>3</sup> with particles of burn eschar at the site of fiber positioning was observed. These lesions were induced by thermal effect of laser radiation<sup>16,19</sup>. No vaporization (fast conversion of liquid to vaporous state due to high temperature) occur at site of laser exposure that is related to application of low power and slow rise of temperature in the focus. In the perifocal area microcirculation disorders typical for laser injuries with stasis and thrombosis in capillaries, with occurrence of blood coagulums, perivascular diapedetic extravasations, and interstitial tissue edema were noted. These data agrees with the findings of other investigators<sup>5,2,23</sup>.

Tissue lesions in the perifocal area due to laser irradiation with microcirculation disorders were detected only at early phase and did not result in complications and did not affect the further dynamics of reparative processes. In the focus of laser destruction feebly marked inflammatory reaction was observed by the end of 2-3 day that had been described for this period by a number of researchers<sup>5,8</sup>. We found that an important feature of reparative processes dynamics in the focus of laser injury was the early formation and manifestation of proliferative component of inflammatory reaction. On 1-3 day of the experiment single fibroblasts appeared along the edge of the focus of thyroid tissue destruction, and by the sixth day their active proliferation with occurrence of macrophagal reaction and feeble manifestation of exudative inflammation component appeared (see Fig.4).

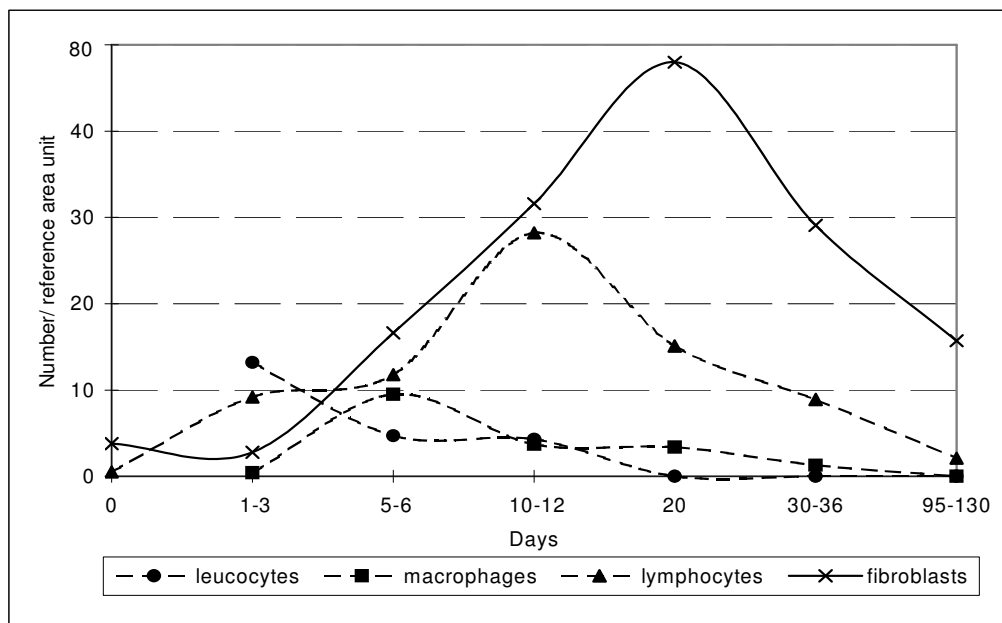


Fig.4. Post-irradiation dynamics of number of cells in the focus of laser destruction.

During the subsequent period proliferation of fibroblasts with increase in number of small vessels of capillary type prevailed. It was accompanied by collagen genesis, initiation and further development of connective tissue scar formation at the site of injury

Thus, by the 10-12 day the period of active growth of granulation tissue was observed, number of fibroblasts, of fuchsinofilous fibers and vessels increased abruptly that conformed with data of other authors<sup>5,2</sup>. It is important to note that the highest fibroblast content was recorded during the 20<sup>th</sup> day of the experiment. This peculiarity is explained by the fact that during the phase of scar remodeling starting from the 10-12<sup>th</sup> day after injury active proliferation of fibroblast line cells

occurs including fibroblasts important for resorption of collagen fibrils. During the later period of the experiment as the scar develops the number of cellular elements, collagen fibers and vessels decreases in it (see Fig.5).

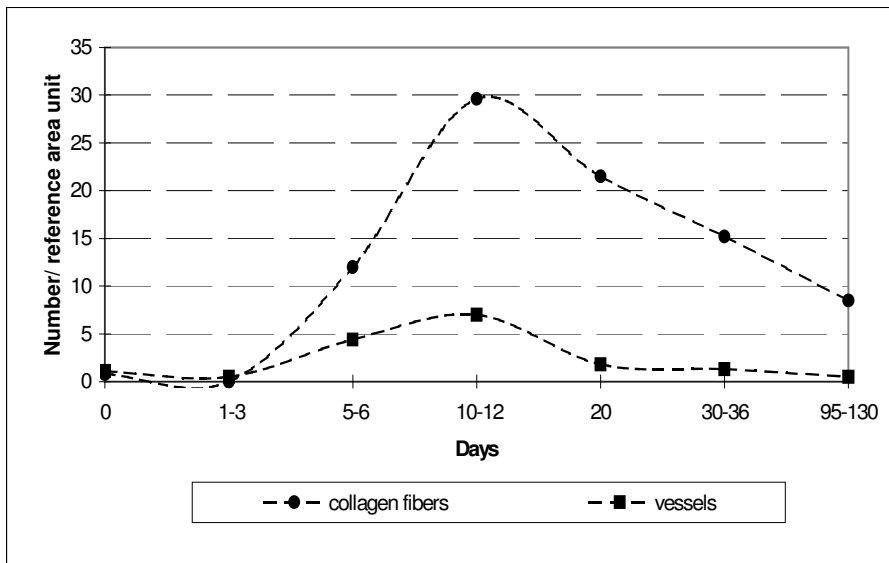


Fig.5. Post-irradiation dynamics of numbers of collagen fibers and vessels in the focus of laser destruction.

Early formation and manifestation of reparative processes after laser irradiation are related to coagulation character of tissue necrosis and small volume of tissue lesions that reduces exudative phase of inflammation and contributes to acceleration of proliferative phase of the reparative process<sup>5,15</sup>.

By the 30-36<sup>th</sup> day vascularized connective tissue scar with dynamics of collagen fibers and vessels quantity decreasing was formed in the focus of laser destruction. In long-term period on the 95-130<sup>th</sup> day the scar was represented by longitudinal small-point growth of connective tissue of 0.7-0.8 cm in length and 0.1-0.2 mm in diameter.

From the early period the local laser lesion was characterized by reversible increasing of functional activity of follicles in perifocal area that was indicated by reduction of colloid accumulation index in them (see Fig.6).

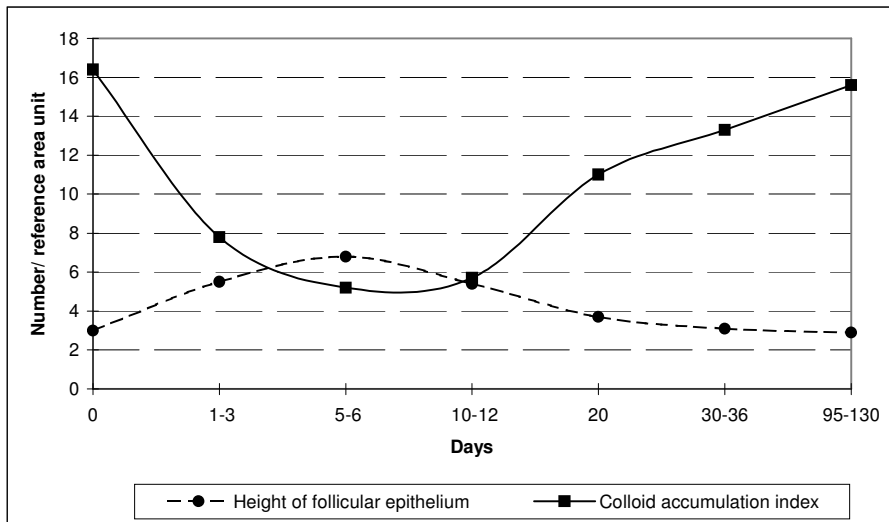


Fig.6. Post-irradiation dynamics of changes in height of follicular epithelium and colloid accumulation index in follicles of perifocal area.

Increase in colloid accumulation index during later period indicated at normalization of functional activity of thyroid that agrees with the studies by Khmelnitskiy O.K. and Tretjakova M.S.<sup>10</sup>.

Determination of thyroid hormones level in dog blood and of thyroid stimulating hormone on the 30, 36, 95, 100, 120, 130 day after laser irradiation showed that their levels did not change (see Table 3).

Table 3 – Average levels of thyroid hormones and TSH before and after laser irradiation

	T3, ng/ml	T4, µg/dl	TSH, µIU/ml
Before laser exposure	1.2±0.1	2.6±0.2	0.6±0.1
After laser exposure	1.2±0.1	2.6±0.2	0.6±0.1

When performing laser surgery the dosing of radiation is of great importance. Its objective criterion is the dynamic temperature monitoring. Dynamic interstitial thermometry allowed to save time and funds upon the selection of adequate laser operating mode. Tissue thermometry during laser irradiation enables to monitor tissue heating dynamics and to interrupt the action at due moment and enhances the safety of the applied method. Thermometry in tissues during laser irradiation showed that at Nd:YAG laser power of 3 W and exposure time of 180 s the temperature of tissue at the point located 1.0 cm from the fiber tip amounted to 46°C and that in adjacent tissues – 40-41°C (see Fig.7).

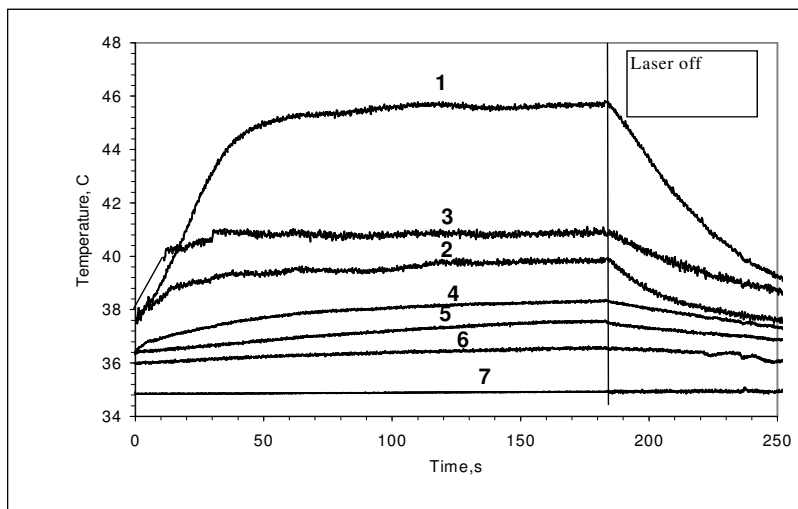


Fig.7. Dynamics of temperature changes in dog thyroid during Nd:YAG laser irradiation (continuous operating mode, power - 3 W, time – 180 s)

Note: Marking of curves in Fig. 7 and 8 coincides with numeration of thermodetector positions in Fig.1.

When the higher power was used, temperatures in the same points of measurement were considerably higher. Thus upon laser irradiation with power of 5 W and time of 60 s the temperature increased up to 85°C and 65°C (see Fig.8).

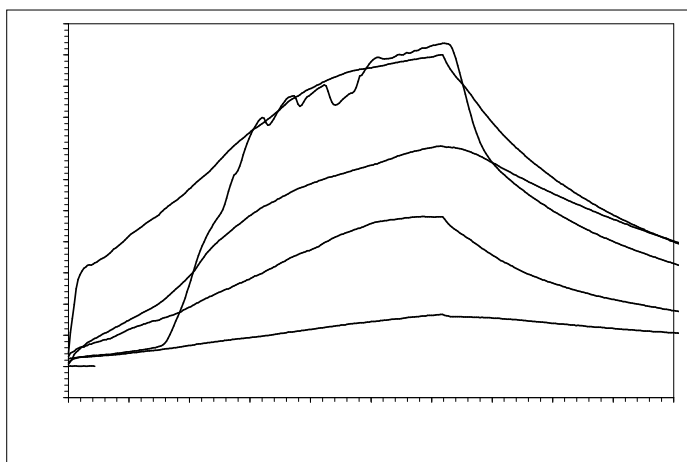


Fig.8. Dynamics of temperature changes in dog thyroid during Nd:YAG laser irradiation (continuous operating mode, power - 5 W, time – 60 s)

In this case the thermal effect was more evident that led to complete destruction of thyroid lobe and lesions of adjacent tissues that corresponded to the data of other authors for laser radiation impact on biological tissues<sup>21,9</sup>.

Thermometry results conform with our histological examination data and indicate at the local character of tissue lesions from laser radiation under conditions selected. However, depending on power and exposure time degree of adjacent tissues damaging can vary. The greater is the power and time of irradiation the wider is the destruction area, and vice versa when decreasing of power and irradiation time the volume of destruction zone reduces<sup>16,13,14</sup>.

We used the advantage of the developed method of dynamic interstitial thermometry during laser irradiation to select adequate operating mode for focal thyroid destruction with diode laser (805 nm) in 10 experiments by monitoring temperature at the boundary between thyroid and adjacent tissues. The most suitable laser irradiation parameters were the pulse duration from 2 to 4 ms, pause duration from 4 to 8 ms, and total time of 1-2 min under the average power of 3W. The total time can be changed depending on the size of growth. Histological examination of thyroid on the 10, 26, 36 day after irradiation showed that diode laser irradiation resulted in similar changes in thyroid and adjacent tissues as compared with Nd:YAG laser and the reparation processes were identical.

Thus the obtained experimental findings give the evidence that the chosen Nd:YAG (1064 nm) and diode (805 nm) lasers operating modes are safe for surrounding tissues and organs and may be used for local laser thermotherapy in clinical practice.

A group of patients with recurrent nodular/multinodular euthyroid goiter was selected for clinical approbation of our method. All the patients had been operated earlier (8-43 years ago). The patients were selected according to the following pre-conditions:

- 1) In these patients the diagnosis was verified either during surgical operation or at routine histological examination of removed specimens.
- 2) The second operation in case of goiter recurrence is more difficult and may have dangerous and serious complications;
- 3) Surgical operation risk in such patients is often higher than illness risk itself, since the considerable number of the patients are elderly people with severe concomitant diseases.

15 patients 40-78 years old (mean age 62 years) with recurrent nodular/multinodular goiter were treated at our clinic. 10 patients had nodular colloid macrofollicular goiter, 3 patients had macro-microfollicular goiter and 2 patients had cystic-mediumfollicular goiter. The focal lymphoid infiltration into surrounding tissue was noted in 5 patients, focal thyroiditis was in 2 patients and there were sclerotic degenerative changes in node and paranodular tissue in 5 patients. After the first operation all the patients have been under endocrinologist observation for several years, they were given thyroid agents in adequate doses under the control of threeiodothyronine level, blood serum thyroxin (T3.T4) and thyrotropic hypophysis hormone (THH). In spite of proper treatment the recurrence of nodular goiter with progressive node growth occurred in all the patients. It was an indication for its destruction. 10 patients complained of discomfort in the neck area, 7- of the difficulty during swallowing, 2- of the respiratory disorders lying on the back; fear of node malignancy (cancerphobia) was the indication for destruction in 3 patients.

All the patients were repeatedly examined after the operation and immediately before laser thermotherapy they were performed thyroid gland trepanobiopsy(thick-needled biopsy). The biopsy findings corresponded with the postoperative histological diagnosis.

Node thermotherapy of thyroid gland was carried on under ultrasonic monitoring by thick-needle transcutaneous puncture. Optical fiber 0,4/0,8mm in diameter was inserted into the node through the needle, the needle moved along the fiber proximally. The local laser thermotherapy was performed. Diode laser with the wavelength of 805nm was used in pulse operating mode as the source of laser radiation. 1-3 procedures of thermotherapy were performed depending on the node size. Laser radiation power was from 2 to 3 W with the operating time of 2-10 min. For the power and time determination we took into account the node size, patient's state and patient's subjective feelings and also the dynamics of visual ultrasonic monitoring during laser thermotherapy. In 1-1,5 minutes after the beginning of thermotherapy on the ultrasound scanner display we could see a hyperechoic "cloud" near the fiber tip (Fig. 9 c). The cloud expanded gradually and "covered" the most part of the node to the end of the procedure (Fig. 9d).



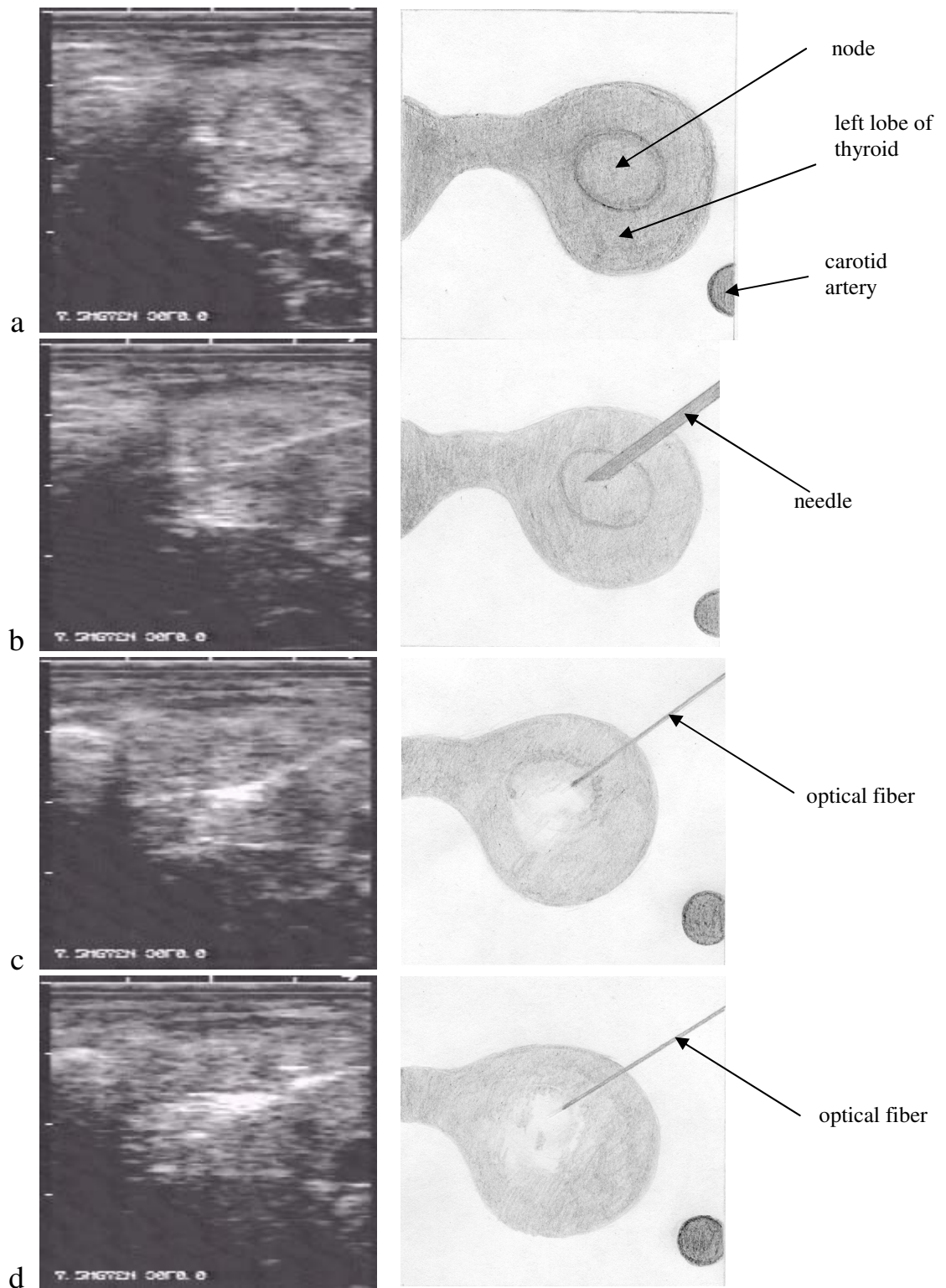


Fig.9. Ultrasonic picture of laser induced thermotherapy of thyroid gland node.

a – Heterogeneous node with dense inclusions in center and hypoechoic border in circumference in the left lobe of thyroid gland; b – The puncture needle is inserted into the node in the left lobe of thyroid with ultrasonic control; c – laser thermotherapy beginning. A hyperechoic “cloud” in the zone of irradiation; d – the end of laser thermotherapy. A hyperechoic zone without clear margins in the node projection.

The changes on the ultrasonic scanograms are associated with a gas formation during the laser thermal action.

All the patients stand the laser thermotherapy well. From the second day after the procedure hypoechoic zone without clear margins have formed in the place of the node. In this period the echo density decreasing is probably caused by edema and aseptic inflammation development. 1-3 months after laser thermotherapy there was the zone of irregular echo texture without clear margins with increasing focal fibrous alterations in the place of the nodes. Later on the ultrasonic picture revealed the node size decreasing and evident fibrous changes in it. During laser irradiation the temperature monitoring was fulfilled in 3 patients. Thermometers (from 1 to 3) were placed along the node margin towards the neurovascular bundle and trachea under ultrasonic control. The nodes of big size required several thermotherapy procedures. 2 procedures were performed in 9 patients, 3 ones per 5-10 days in 6 patients. The duration of observation varies from 3 months to 1 year. In 5 patients during 6 months period the node decreased by 1/2 and in 4 patients-by 1/3. The growth of the nodes was not noted in any of them. After local laser thermotherapy thyroid gland functional state did not suffer, that was proved by clinical investigations and biochemical tests (T3, T4 and TSH levels did not change).

Taking into consideration the positive clinical effect of laser induced thermotherapy in patients with recurrent goiter, we used this method in treatment of 2 patients with thyroid medullary carcinoma, IV grade. Both patients received symptomatic treatment after palliative surgery and gamma-teletherapy on thyroid gland and mediastinum. Despite of the combined treatment there was not the tumoral process stabilization, the signs of compression syndrome were becoming worse.

Here is a case report:

Patient E, 50 years old. In December 1997 thyroidectomy was performed apropos of thyroid medullary carcinoma (T3N1M0). In 3 months, in March 1998, the recurrence of the disease occurred. Tracheostoma was applied and the course of X-ray therapy (40 Gy) was carried out. Patient's state became stable, but the tumor regress was not noted. In March 1999 two procedures of intratissue laser thermotherapy were performed with the diode laser (805 nm) ( power of 3 W, pulse operating mode, time 4 and 5 minutes) with the interval 6 days between the procedures under ultrasonic monitoring. During laser thermotherapy there were unpleasant feelings, mild pain in the neck area persisted for 1,5-2 days. On the 2-nd day swelling occurred in the neck area, it was also marked the reduction of node echogenicity at ultrasonic examination, inaccuracy and vagueness of its margins. In 5 days after the second procedure the patient was discharged from the hospital for out-patient observation. 1,5 month later the patient felt relief, the neck tumor reduced, neck tissue tension disappeared, the breathing through tracheostoma became better. During the summer the patient worked much about the house and in the garden. In 6 months at the examination the patient's state was satisfactory. The neck tumor was not almost determined on palpation, lymphatic nodes were not palpated. Tracheostoma was formed well. At ultrasonic examination in the thyroid right lobe projection on the background of heterogeneous tissue of medium echogenicity the hypoechoic node was determined, 2x2 cm in size, without sharp margins. Neck and mediastinum tomograms did not reveal any pathology. (Fig. 10)

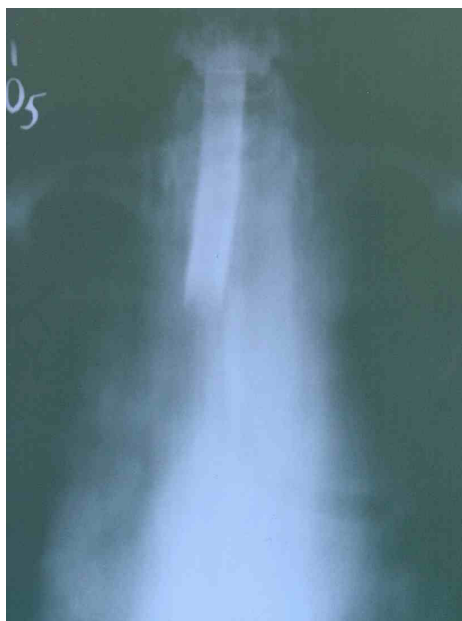

Fig.10 X-ray tomogram of neck and mediastinum of the patient E. The mediastinum shade is not dilated, metallic cannula is in trachea.

In September 1999 two more procedures of thyroid cancer laser thermotherapy were performed. The patient was discharged from the hospital and was well enough to be observed at the out-patient department.

Our experiments and the first clinical experience of the new developed method of transcutaneous laser interstitial thermotherapy of the thyroid nodular growths show the promising character of this method. The further research and the analyze of remote results are necessary.

#### 4. REFERENCES

1. Aleksandrov Y.K., *Puncture methods in diagnostics and treatment of thyroid disease*. Yaroslavl 1996. (in Russian).
2. Astakhova L.V., Giniatullin R.U., Bordunovskiy V.N., Bondarevskiy I.Y., Penin K.S., Pivovarov A.G., Guzhina A.O., Kilin D.G., "General and particular regularities of reparative and adaptive processes in biological tissues after exposure to laser radiation of high intensity (experimental study)", *Laser technologies in medicine, collected abstracts of Chelyabinsk State Institute of Laser Surgery*, Chelyabinsk, pp. 64-69, 1998. (in Russian).
3. Chapman R., "Percutaneous laser-induced interstitial thermotherapy for the treatment of very large uterine leiomyomas", *Problems of laser Medicine*, pp. 139, Moscow-Vidnoje-Russia, 1997.
4. Dzhaubaev M.O., Ionov P.M., "Surgery at recurrent goiter", *Khirurgia* **6**, pp.123-124, 1989. (in Russian).
5. Eliseenko E.I., "Morphology of reparative processes at exposure to continuous laser radiation", *Sovetskaya meditsina* **1**, pp.20-26, 1987. (in Russian).
6. Hegedus L., Nygaard B., Hansen J.M., "Is routine thyroxine treatment to hinder postoperative recurrence of nontoxic goiter justified", *J. Clin. Endocrinol Metab.*, **84(2)**, pp. 56-60, 1999.
7. Hurley D.L., Gharib H., "Evaluation and management of multinodular goiter", *Otolaryngol. Clin. North. Am.*, **29(4)**, pp.527-540, 1996.
8. Ismagilova, S.T., *Dynamics of morphological changes in trigeminal nerve after the destruction of its sensitive root with laser radiation of high intensity, dissertation for candidate of medical science*, Chelyabinsk, 1997. (in Russian).
9. Ivarsson K., Olsrud J., Stureson C., Moller P. H., Persson B.R., Tranberg K.-G., "Feedback Interstitial Diode Laser (805nm) Thermotherapy System: Ex Vivo Evaluation and Mathematical Modeling With One and Four-Fibers.", *Lasers in Surgery and Medicine* **22**, pp.86-96, 1998.
10. Khmel'nitskiy O.K., Tretjakova M.S., "Thyroid as a subject of morphometric examination", *Arkhiv patologii* **4**, pp.47-49, 1998. (in Russian)
11. Kozlov V.I., "Modern directions in laser medicine", *Lasernaya meditsina* **1**, pp. 6-12, 1997. (in Russian).
12. Lappa A. et.al., "Contact thermometry in intensive fields of laser radiation", *SPIE Proceedings*, **3565**, pp. 90-100, 1998.
13. Littmann L., Svenson R.H., Chuang C.H., et.al., "Neodymium: YAG contact laser photocoagulation of the in vivo canine epicardium: dosimetry, effects of various lasing modes, and histology", *Lasers Surg. Med.*, **13(2)**, pp.158-167, 1993.
14. Miyaguchi M., Sakai S., "The contact Nd-YAG laser for oral and oropharyngeal malignant tumors", *Auris Nasus Larynx*, **21(4)**, pp.226-231, 1994.
15. Nevorotin, V.I., Kul, M.M., "Electronic-histochemical characteristic of laser-induced necrosis", *Arkhiv patologii* **7**, pp. 63-69, 1989. (in Russian).
16. Pletnev S.D., "Lasers in clinical medicine", *Manual for physicians Pletnev, S.D. (Ed.)*, Meditsina, Moscow, 1996. (in Russian).
17. Pluzhnikov M.S., Leskin G.S., Em En Gir, "Some aspects of endolaryngeal laser surgery", *Actual problems of Laser medicine*, pp. 49-51, Meditsina, Moscow, 1990. (in Russian).
18. Shukhgaltier I.A., Boyko A.N., Burchenkov B.I., et.al., "Diagnostics and treatment of recurrent goiter", *Khirurgia* **4**, pp.35-41, 1990. (in Russian).
19. Sulser T., Jochum W., Huch Boni R.A., et.al., "MRI-correlated morphological changes after Nd:YAG laser treatment of the human prostate with the Side Focus fiber", *Urol. Int.*, **59(1)**, pp. 34-40, 1997.
20. Toropov, Y.D., Izbitskiy, V.I., Vysotskiy, V.N., "Diagnostics and treatment of nodular euthyroid and toxic goiter", *Khirurgia* **7**, pp. 81-85, 1991. (in Russian).
21. Tuchin, V.V., "Introduction into the optics of biotissues", *Lectures*, Moscow, 1995. (in Russian).
22. Vestergaard E.M., Jensen V.J., Nielsen H.O., "Surgical treatment of goiter at a central hospital. A consecutive study with special emphasis on surgical complications", *Ugeskr. Laeger.*, **157(43)**, pp. 5979-5982, 1995
23. Weber H.P., Heinze A., Enders S., et.al., "Laser catheter coagulation of normal and scarred ventricular myocardium in dogs", *Lasers Surg. Med.*, **22(2)**, pp.109-119, 1998.