Diode laser osteoperforation and its application to osteomyelitis treatment

Valery A. Privalov[*a d], Igor V. Krochek[** b], Alexander V. Lappa[*** c d]

[a]Chelyabinsk state medical academy; [b]Chelyabinsk municipal clinical hospital №1;
[c]Chelyabinsk state university, [d]Chelyabinsk state institute of laser surgery

ABSTRACT

Laser osteoperforation, previously studied in experiment in rabbits at treatment for acute purulent osteomyelitis (Privalov V. et.al., SPIE Proc., v.3565., pp. 72-79), was applied in clinic to 36 patients with chronic purulent osteomyelitis and to 6 patients (children) with acute haematogenic osteomyelitis. Diode lasers of 805 and 980 nm wavelength were used. There was achieved full recovery in all acute cases, and stable remission in chronic cases during all the observation period (1 – 2.5 years).

Keywords: osteomyelitis, osteoperforation, laser, clinical application

1. INTRODUCTION

The success in treatment of acute haematogenic osteomyelitis, that was reached in past years due to opportune diagnostics and early adequate treatment, including surgery, does not exclude the risk of disease to become chronic, development of functional and cosmetic defects, disablement of patients. At the same time many surgical methods are traumatic and insufficiently grounded. Therefore the problem of the improvement of acute haematogenic osteomyelitis treatment and of the patients' quality of life remains actual, and is as before of intense interest for investigators [1,2,3,].

In the past years there have been developed new technologies with the application of different physical factors affecting the inflammatory processes in endosteum, paraosseous area and periosteum. Radiation of high-energy lasers is among these factors [3,4]. The laser radiation action on organism tissue demands detailed study so as to clarify the possibility of its application to treatment of acute haematogenic and chronic osteomyelitis.

Earlier in experiment in rabbits we showed that near infra-red laser beam allows osteoperforation (making holes in bones) and applied this effect to treatment for experimental acute purulent osteomyelitis [3]. In this work we present the first clinical experience of application of laser osteoperforation to human osteomyelitis treatment.

2. MATERIALS AND METHODS

We analyzed the results of treatment of 52 patients with different forms of osteomyelitis. Experimentally developed method of laser osteoperforation [2,3] was applied to 36 patients with chronic osteomyelitis and to 6 patients with acute haematogenic osteomyelitis. 10 children with acute haematogenic osteomyelitis formed a comparison group. They were subjected to open mechanical osteoperforation with drill (perforator 2 mm. in diameter) under influx-and-extract draining.

* privalov@cgilh.chel.su; phone +7 (3512) 346304; fax +7(3512)347542, Chelyabinsk state medical academy, 16 Vorovskogo, Chelyabinsk, 454092, Russia; Chelyabinsk state institute of laser surgery, 287 pr. Pobedy, Chelyabinsk, 454021, Russia; ** phone +7 (3512) 345965; fax +7(3512)347542, Chelyabinsk municipal clinical hospital №1, 16 Vorovskogo, Chelyabinsk, 454092, Russia; *** lappa@cgu.chel.su; phone +7(3512)189235; fax: +7(3512)420925, Chelyabinsk state university, 129 Br. Kashirinykh, Chelyabinsk, 454136, Russia; Chelyabinsk state institute of laser surgery, 287 pr. Pobedy, Chelyabinsk, 454021, Russia.

Laser-Tissue Interactions, Therapeutic Applications, and Photodynamic Therapy,
Reginald Birngruber, Hubert van den Bergh, Editors, Proceedings of SPIE Vol. 4433
(2001) © 2001 SPIE · 1605-7422/01/$15.00

Apart from clarification of anamnesis and physical examination the patients were subjected to biochemical, bacteriological, instrumental, cytological, ultrasonic, rontgenological and radioisotope investigations. So as to perform early diagnostics of acute haemotogenic osteomyelitis and to make a prognosis of purulent complications after operation there was applied non-invasive method of transcutaneous oxygenometry with the apparatus TCM–2 (firm "RADIOMETER") [5].

The possibilities of early and non-invasive diagnostics of osteomyelitic process with application of standard methods (rontgenography, computer tomography, distant thermography, rheovasography, etc.) are limited. We used our method of comparative transcutaneous oxygenometry of extremities aimed at its application in case of suspicion of acute haemotogenic osteomyelitis [1]. This method meets the requirements of little invasiveness, high effectiveness and early diagnostics. As is well known in the first hours of development of inflammation there are microcirculation failures [1,5], integral expression of which is the decrease of oxygen partial tension in tissues of affected segment of extremity [1,5,6]. The change of oxygen tension in tissues allows us to determine if inflammation is present or absent.
Decrease of oxygen partial tension on the affected segment of extremity, comparing to healthy extremity by 25-50%, was noticed in all children with acute haemotogenic osteomyelitis. This circumstance allows us to diagnose acute haemotogenic osteomyelitis during first hours after the beginning of the disease.

All patients had osteomyelitis of localized form. Distribution of children with acute haemotogenic osteomyelitis on the anatomic localizations is presented in table 1.

Table 1. Localizations of acute haemotogenic osteomyelitis

№	Localization	Group 1 (laser)	Group 2 (comparison)
1	thigh-bone	2	3
2	shin-bone	2	4
3	pubic bone	1	1
4	Calcaneum	1	2
	TOTAL	6	10

The clinical situation in both groups was identical and manifested in marked signs of endogene intoxication with leucocytosis, shift of blood formula to the left, lymphopenia, moderate anemia. Local manifestations of acute haemotogenic osteomyelitis were characterized by pain in corresponding metaepiphyses of extremity bones, non-localized pain at palpation, moderate edema of affected segment of extremity, tension of tissues, local increase of temperature and positive symptoms of axial load. Bacteriological investigations of punctured marrow of children from both groups showed the presence of goldish staphylococcus in pathological concentration $10^6 – 10^7$ 1/g.

25 patients with chronic osteomyelitis had fistulous form of disease, 11 – non-fistulous. All the patients were repeatedly treated and operated without success. Duration of disease varied from 6 months to 43 years. Rontgenologic investigation revealed sequestrums in 21 patients of 36 chronic osteomyelitis patients.

Distribution of patients with chronic osteomyelitis on the anatomic localizations is presented in table 2.

Table 2. Localizations of chronic osteomyelitis

№	Localization	Chronic posttraumatic osteomyelitis	chronic haematogenic osteomyelitis
1	thigh-bone	6	1
2	shin-bone	12	1
3	splint-bone	2	-
4	calcaneum and foot bones	6	-
5	humerus	2	1
6	ulna	1	-
7	radius	3	1
8	TOTAL	32	4

Before operation we punctured marrowy canal with the Kassirski needle in order to get the smear-mark and to conduct bacteriological test. The marrowy canal was drained with a catheter (1-2 mm in diameter), inserted through the needle, so as to perform dynamic bacteriological investigations later on.

. For laser perforation we used diode lasers with wavelength 805 and 980 nm in pulse-periodic mode. Beam energy was delivered to the affected bone transcutaneously by means of a quartz monofiber (0.4 mm in diameter). Parameters of laser irradiation were previously found in experiments on cadaveric human bones and on animal bones in vivo. Experiments included the study of temperature fields in the irradiated zones with the special setup allowing for temperature difference between thermodetector and medium surrounding it [2,3].

At the chronic osteomyelitis we punctured soft tissues to the bone with a needle (diameter 1-1.2mm) under intravenous or local anaesthetic. Then we conducted the fiber through the needle and perforated the bone up to marrowy canal. 10-20 perforations in projection of rontgenologically determined foci of bone destruction at intervals about 1 cm are made. If there were fistulas we in addition performed the laser treatment of all fistula way for 30-40 seconds at the power 3-5 watt. At that the pus with small (up to 0.2 cm) sequestrums was “boiled-off” through the fistulas.

At the acute haematogenic osteomyelitis the perforations were formed under general intravenous anaesthetic in interperpendicular flats over all the metaepiphysis of the affected segment of extremity at intervals 1 cm.

3. RESULTS AND DISCUSSIONS

There were applied different operating modes and manners of laser osteoperforation to treatment of patients with acute haemotogenic and different forms of chronic osteomyelitis. We found out that 10-15 watt of average power of laser radiation during 3-10 seconds under pulse-periodic mode results in osteoperforation of all the layers of compact bone. These modes do not cause deep thermal lesions of soft tissues and bones; the formation of small bone fragments, which appear at the mechanical osteoperforation, is excluded. Besides, the hyperthermy caused by laser radiation strongly sanifies marrow and surrounding tissues.

All the patients with acute haemotogenic osteomyelitis, who were subjected to laser osteoperforation (first group), marked that after the operation pain became calmer. Clinical improvement occurred on the 2nd – 3^{d} day and was accomponied by decrease of tension and edema of soft tissues, by normalization of appetite, decrease of tachycardia. In comparison group (after mechanical osteoperforation) the improvement occurred on the 4th – 5th day after the operation. Duration of hyperthermia in the laser group was reliably shorter than in the comparison one. Leucocyte index of intoxication (LII) and level of mid-molecular peptides (MMP) in the first group of children decreased faster comparing to the same characteristics of children from the second group. The duration of stationary treatment decreased reliably. Results of the treatment are presented in table 3.

Table 3. Results of treatment of children with acute haemotogenic osteomyelitis.

Effectiveness criteria	Mechanical osteoperforation (10 patients)	Laser osteoperforation (6 patients)
Hyperthermia duration (day)	**4,6±0,4**	**2,5±0,2**
LII (arbitrary unit)	**3,2±0,3**	**0,77±0,05**
MMP (arbitrary unit)	**0,33±0,02**	**0,26±0,02**
Stationary treatment duration (day)	**19±2**	**12±2**

In the laser group of children during all observation period there occurred no purulent inflammatory changes in soft tissues of operated zone. Two complications were marked in the comparison group after open mechanical osteoperforation with influx-and-extract draining of paraosseus tissues. In the first case it was a tensed “hydroma” caused by failure of outflow of antiseptic solution in draining system, in the second case it was intermuscular

phlegmon. Both children were operated once more. In the first case the child recovered, in the second case the process became chronic.

Dynamic bacteriological investigation showed that in the laser group of children the sanitation of pathologic focus and decrease of number of microorganisms below critical level went considerably faster than in the comparison group. The Results are presented in table 4.

Table 4. Number of microorganisms per a gramm of material from marrowy canal of children with acute haemotogenic osteomyelitis.

Groups of children	1 day	2 day	3 day	4 day	5 day	6 day	7 day
laser osteoperforation	**10^7**	**10^5**	**10^3**	**-**	**-**	**-**	**-**
mechanical osteoperforation	**10^7**	**10^6**	**10^6**	**10^5**	**10^4**	**10^3**	**-**

All children from the laser group recovered. They have been under observation during 8-14 months and feel well. In comparison group the process became chronic in 1 case of 10.

Laser osteoperforation in cases of chronic osteomyelitis resulted in stable remission in 34 cases of 36. In 2 patientes with large sequestrums and almost total destruction of the bone purulent process was not stopped despite repeated (3 and 4 times) laser osteoperforation. Nevertheless there was a significant improvement of general state of these patients that allowed us subsequently to conduct trough-shaped resection of bone with sequestrumectomy. In 17 of 25 cases with fistulous osteomyelitis the fistulas were closed in 4-10 days after treatment, in 7 cases they were closed in 11-18 days. In 1 case with large sequestrum the fistula did not close but the quantity of exudate decreased considerably. Subjectively all the patients consider themselves to be recovering, objective data show the stable remission.

Below we present clinical observations of 2 patients treated with laser osteoperforation.
1. Patient Sh., 14 years old, male. He was hospitalized in purulent surgery ward on 29.12.1999 with acute haemotogenic osteomyelitis of distal metaepiphysis of thigh-bone complicated with osteomyelitic phlegmon of thigh. Patient was ill for 5 days. He was operated urgently. There was conducted the cut of the phlegmon and mechanical osteoperforation of distal metaepiphysis of thigh-bone with arrangement of influx-and-extract draining of paraosseus area. The patient was discharged from hospital in satisfactory state with healed up wound on 27th day. In three weeks the fistula opened on inner surface of the thigh in the lower third. Long-term conservative treatment included sanitation of the fistula, application of antibiotics and metronidasol, immunotherapy with gamma globulin, DMSO electrophoresis, etc. The treatment was not very effective. Fistula closed for 7-12 days and then opened again. The operation of laser osteoperforation of the middle and the lower third of the thigh-bone was performed on 26.04.2000. The patient was discharged from hospital in 11 days with the closed fistula and in a good state of health. In 11 months there was a control examination, there were no complaints, no fistulas. The patient felt healthy. The rontgenogram of patient Sh. before and after laser osteoperforation is presented on fig. 1.

2.Patient P., 44 years old, female. Patient considers herself to be ill for a year after the open fracture of the middle third of the left splint-bone on 21.10.1999. Periodically there appears edema, reddening, skin tension in the middle third of the shin, that was accomponied with high temperature up to 39-39.5^{0}C. Patient was treated with antibiotics, immobilization, physiotherapy. The state improved but in 2-3 months there was a recurrence. Patient was directed to the consultation and operation. Laser osteoperforation of splint-bone was performed on 27.10.2000. The state improved. Patient was discharged from hospital in 7 days. Control examination was conducted in 5 months. There were no complaints. There were marked no hyperthermy and pain. Rontgenograms of patient P. before and after laser osteoperforation are presented on fig. 2.

4. CONCLUSION

The first experience of clinical application of laser osteoperforation to different forms of purulent osteomyelitis indicates the efficacy of this method of treatment. Unlike mechanical osteoperforation it is less traumatic, quickly normalizes interosseus pressure, possesses marked sanitation effect, causes destruction of pathogenic microflora; all these factors result in elimination of inflammation focus in a bone. Subsequent accumulation of clinical data would

allow us to develop this method in detail, specify some mechanisms of laser radiation action and indications and contra-indications to the treatment.

Fig. 1. Rontgenograms of patient Sh., 14 y.o. , with acute haemotogenic osteomyelitis of the right thigh.
a)Before laser osteoperforation. Thigh-bone in middle and lower third is thickened and deformed because of marked periostitic formations, partially assimilated. There is a significant destruction of bone tissue along bone cylinder in the diaphysis and metaphysis area.
b) In 11 months after laser osteoperforation. There is a small thickening in the middle and the lower third of the thigh-bone. The structure of the bone is reconstructed due to osteosclerosis. There are no sequestrums and destruction area.

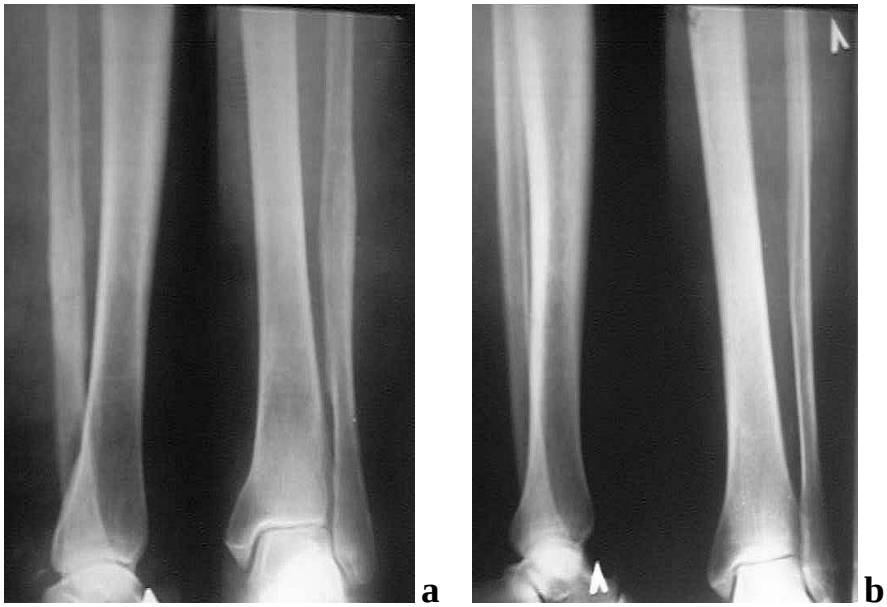

Figure 2. Rontgenograms of patient P., 44 y.o. , with chronic osteomyelitis of splint-bone.
a) Before laser osteoperforation. Splint-bone is deformed and thickened due to periostitic formations in the middle third. Marrowy canal is narrowed. No destruction area is marked.
b) In 5 months after laser osteoperforation. Bone structure is restored. Marrowy canal is not narrowed; it is seen all over. No bone destructive changes are noticed.

REFERENCES

1. I.A. Abushkin, , I.V. Krochek and V.A. Privalov, "Method of Diagnostics of Acute Haemotogenic Osteomyelitis", *patent of Russia № 2124723 on request № 97102946*, 1997. (In Russia)
2. A.V. Lappa, A.A. Kazakov, S.I. Veresov, V.A.Privalov et al., "Contact thermometry in intensive fields of laser radiation", *Thermal Therapy, Laser Welding, and Tissue Interaction*, Stephen G. Bown et al. editors, proceedings of SPIE, vol. 3565, pp. 90-100, 1998.
3. V.A. Privalov, A.L .Svetlakov, O.S. Kuchakovsky, A.V. Lappa, A.A. Kazakov, A.I. Kozel, "Hyperthermal effect of laser osteoperforation in treatment acute purulent osteomyelitis", *Thermal therapy, laser welding, and tissue interaction*, Stephen G. Bown et al. editors, proceedings of SPIE ,vol. 3565, pp. 72-79, 1998.
4. Y.K. Maker and R.L. Kaplan, «Contact neodymium-yttrium-aluminium garnet laser acts as a sterellizing scalpel», *Surg. Gynecol. Ostetr*., vol. 170, № 1, pp. 17-20, 1990.
5. V.A. Privalov, I.A. Abushkin, I.V. Krochek, V.G. Abushkina and T.V. Katunkina, "Early diagnostics and control of efficacy of treatment of children with acute haemotogenic osteomyelitis with the help of intratissue oxygenometry", *First Byelorussian International Congress of Surgeons*, pp.82-84, Vitebsk, 1996. (In Russian).
6. A.V. Pokrovsky, V.N. Dan and A.V. Chupin, "Experience of Vasaprostan Application to Treatment of Patients With Critical Ischemia of Lower Extremities", *Vasaprostan*, pp.7-11, Moscow , 1995. (In Russian).